

Research Journal of Pharmaceutical, Biological and Chemical Sciences

To Compare and Evaluate the Clinical Performance and Retention of Two Different Types of Glass Ionomer Cements for Class I Restorations in Primary Molars.

Sandeep Bailwad¹, Navin Patil^{2*}, Nuvvula Sivakumar³, Balaji O⁴, Ashwin KS⁵, Yogesh Chhapparwal⁶, Shubha Chhapparwal⁷.

¹Senior Lecturer, Department of pediatric dentistry, MAHSA University, Malaysia.

²Assistant Professor, KMC Manipal, Manipal University, Manipal, Karnataka, India.

³Professor and Head, Department of pedodontics, Narayana Dental College, Nellore, Andhra Pradesh, India.

⁴Postgraduate, Manipal University, Manipal, Karnataka, India.

⁵Lecturer, Department of Prosthodontics, MAHSA University, Malaysia.

⁶Associate Professor, Manipal College of dental sciences, Manipal University, Manipal, Karnataka, India.

⁷Assistant Professor, Manipal College of dental sciences, Manipal University, Manipal, Karnataka, India.

ABSTRACT

Pediatric Restorative Dentistry plays a major role in the management of carious primary teeth. Pediatric Dentistry has come a long way, retrospectively different tooth colored restoratives were used to treat carious teeth and the first of them being the silicate cements till the emergence of GICs, the present era of Nano technology has given a new dimension to all aspects of dentistry including restorative dentistry, by incorporating nano sized filler particles. Among all the broader scope of pediatric dentistry, conservative restoration of primary teeth continues to be the most important issue today. This study was undertaken to evaluate and compare the survival rate of RMGIC and conventional GICs along with secondary caries detection in class I cavity preparations in primary molars. The results of the present study depict the fact that both materials performed clinically good for a period of 6 months the resin-modified Nano Ionomers showed lower rates of failure and offered advantages over the conventional GIC for restoring class I caries in primary molars.

Keywords: Resin modified glass ionomer cements (RMGIC), Glass Ionomer Cements (GICs), Caries, Restorative Technique.

**Corresponding author*

INTRODUCTION

Pediatric dental care is an integral component of a child's overall wellness. Provision of this optimal oral healthcare comes under the purview of all dentists and in particular Pedodontist's. Among all the broader scope of pediatric dentistry, conservative restoration of primary teeth continues to be the most important issue today [1]. Till date, most of the restorative materials used have inherent shortcomings, such as mercury toxicity associated with amalgam, initial poor strength of glass ionomer cements, polymerization shrinkage and micro leakage associated with composites as also, the unaesthetic appearance of stainless steel crowns. In the current era of adhesive dentistry, newer glass ionomer cements offer the following advantages

- A coefficient of thermal expansion similar to that of tooth structure
- A physicochemical bond to enamel and dentin and
- Fluoride release from the restoration[2].

However, its compressive strength is questionable as is its wear resistance and color stability in posterior teeth. To overcome these shortcomings, restorative materials that incorporate light curable resin and increased filler content, like resin modified glass ionomer cements (RMGIC), were developed. The command set of RMGIC resulted in the early development of higher bond strength, reduced brittleness, lower moisture sensitivity, reduced solubility and wear resistance and it has antibacterial characteristics also. These cements have demonstrated success by inhibiting secondary caries at restoration margins and have the ability to enhance remineralization by inhibiting adjacent proximal caries [3]. G.V. Black's principles of cavity preparation for permanent teeth, although initially considered the gold standard in primary teeth, are not relevant today. The restoration of primary teeth using adhesive materials warrants non-adverse conditions in cavity preparation. Therefore, some of the major differentiating factors in pediatric restorative dentistry are cavity design and preparations that consider the morphologic variations such as a narrower occlusal table, a reduced thickness of enamel and dentin, high pulp horns and altered tooth composition[4]. Within the currently available literature, there are only a few studies that evaluate the survival rate of adhesive resin in primary teeth. Adhesion between the restorative material and tooth structure is the major determinant in the success of a restoration. If the state of bonding is poor, micro leakage at the cavity margins is inevitable leading to secondary decay, marginal pigmentation and pulpitis. To overcome this limitation, beveling the cavity margin to increase the available bonding area has been proposed and in vitro studies have shown there is a decrease in micro leakage in cavities with beveled margins [5]. Very few clinical trials have been undertaken or documented to evaluate the clinical performance of RMGIC in comparison with the conventional Glass Ionomer cements (GIC). This study was undertaken to evaluate and compare the survival rate of RMGIC and conventional GICs along with secondary caries detection in class I cavity preparations in primary molars.

Aim

To compare and evaluate the clinical performance and retention of two different types of Glass Ionomer Cements (GICs) for class I restorations in primary molars.

MATERIALS AND METHODS

The present in-vivo study was designed and conducted in the Department of Pedodontics and Preventive Dentistry, Narayana Dental College, Nellore. To compare and evaluate the clinical performance of conventional GIC (Fuji IX TM) versus light cured RMGIC (Ketac TM Nano restorative).

The following are the list of materials and armamentarium used in this study.

- For Screening, a sterile kit consisting of Stainless steel kidney tray, Mouth mirror, Straight probe, Tweezers, Explorer, Gloves, Mouth mask and an antiseptic solution - Dettol® Reckitt Benckiser (India) Ltd.
- Armamentarium for caries excavation and restoration, a sterile kit consisting of Gloves, Mouth mask, Stainless steel kidney tray, Mouth mirror, Explorer, Straight probe, Tweezers, Cotton wool rolls, Spoon excavator, William's Graduated Periodontal Probe, High speed suction kit, High speed Air Rotor hand

piece (NSK[®], Japan), Burs (round, straight and inverted cone) size 002 Mani burs[®], Dappen dish, Cement carrier, Agate's spatula, Condensers (round and parallelogram).

- Restorative Materials Ketac[™] Nano Light Curing Glass Ionomer Restorative and Ketac[™] Nano Primer (3M ESPE)[®] Fuji IX TM, Gold Label High Strength Posterior Restorative Glass Ionomer Cement (GC corporation Japan)[®]
- Miscellaneous - Petroleum jelly - Vaseline[®], Palmolive (India) Ltd. Radiovisiograph (RVG) IOPA radiographic films, size 2 (Kodak[®]) E speed

Method

A controlled, randomized, split mouth, six months prospective clinical study was conducted to compare and evaluate the clinical performance of conventional GIC (Fuji IX TM) versus light cured RMGIC (Ketac TM Nano restorative) in bilateral Class I cavities of mandibular second primary molars. 60 children aged between 4-7 years, were selected irrespective of race or socioeconomic status by a simple random sampling technique from different schools in and around Nellore city and also from the patients attending the regular out patient in the department of Pedodontics and Preventive Dentistry, Narayana Dental College and Hospital, Nellore. Parental consent and clearance from the Ethical Committee were obtained prior to the procedure and a routine oral examination was done for all the children.

Inclusion Criteria

- Caries involving bilateral mandibular second molars
- Caries involving only the occlusal surfaces of the tooth
- Caries involving the enamel and dentine
- Caries involving a depth of 2 mm or less from the occlusal surfaces of the tooth towards the dentine.

Exclusion Criteria

- Any history of pain experienced in the tooth
- Any pathologic mobility present in the tooth
- Caries extending beyond a depth of 2mm from the occlusal surfaces of the tooth towards the dentine.
- Physically or mentally disabled children
- Medically compromised children
- Patients with extreme caries activity and conditions which were expected to cause the loss of the treated tooth within the 6 months follow-up period.

RANDOMIZATION

The total sample of children was further divided into two groups based on gender as 30 girls and 30 boys. In each patient carious bilateral mandibular second primary molars were divided randomly into two groups according to the allocation of the materials, which was decided by tossing a coin. On one side the mandibular second molar was restored with conventional glass ionomer cement (Fuji IX GP TM) and on the other side light cured resin modified Nano ionomer (Ketac N100 TM) was used. 60 children (120 teeth) were divided into 30 boys (60 teeth) and 30 girls (60 teeth), 30 boys (60 teeth) divided into Conventional (30 teeth) and RMGIC (30 teeth), 30 girls (60 teeth) divided into Conventional (30 teeth) and RMGIC (30 teeth).

In both the groups, the type of the lesion was determined by the presence of caries only on the occlusal surface with a mouth mirror and a right angled straight probe/explorer. If there was presence of any soft caries excavation was carried out with a sharp spoon excavator. Later, class I cavities were prepared bilaterally on the mandibular second primary molars. A high speed rotary instrument (Airotor) with coolant along with round, straight fissure and inverted cone diamond burs (Mani Dia burs[®] of size 008 designed for pediatric patients) were used for this purpose. Restorations were placed bilaterally on right and left mandibular 2 ND primary molars by a single operator. The depth of the cavity was standardized to 2mm, by measuring with William's graduated periodontal probe. Isolation of the tooth was done with cotton rolls and high pressure suction in place. Caries excavated with a sharp spoon excavator initially if there was presence of any soft caries.

The allocation of the restorative material was randomly done on either side of the mouth & in all cases a split mouth technique was used by tossing a coin. Patients were blinded to the techniques used.

DISPENSING AND MIXING OF THE RESTORATIVE MATERIALS

Group I: - Conventional Glass Ionomer cement (Fiji IX GP TM)

Powder and Liquid Dispensing: The standard powder to liquid ratio used was 1 level scoop of powder to 1 drop liquid (3.6 grams to 1 gram) according to manufacturer's instructions. **Mixing:** After the powder and liquid were dispensed onto the mixing pad. The powder was divided into 2 equal parts. The first portion of the powder was mixed with all the liquid for 10 seconds using Agate's spatula and then the second portion was incorporated and mixed thoroughly for 15-20 seconds in rolling and folding motion. The standard working time of the cement being 2 minutes was reduced due to the increased climatic temperatures to 1 minute and 30 seconds.

Placement: The dental instruments used for shaping and contouring were coated with Vaseline to prevent glass ionomer restorative from adhering to them. Working time was slightly lesser of about 1 minute and 30 seconds due to the increased temperature.

Finishing: Final finishing using high speed Aerotor under water spray and finishing burs was done after 6 minutes from the time of starting the mix and the patient was instructed not to apply pressure on the restored tooth for a period of 1 hour after placement of the restorations.

Group II: - Resin Modified Nano Ionomer Cements (Ketac N100 TM)

Primer Ketac™ N100 Nano Glass Ionomer Primer was applied to the preparation before restoring tooth according to the steps mentioned. The primer was dispensed into a well. Then using a fiber brush tip, application of the primer was done for 15 seconds to prepared semi-dry enamel and dentin surfaces. Replenishing primer as needed to assure surfaces were kept wet with primer for the recommended application time. The primer was dried using an air syringe for 10 seconds without rinsing. After drying, the primed surfaces were shiny in appearance. The primer was light cured for 10 seconds using a dental visible light curing Dentsply® (Mallifer TM) unit of comparable intensity.

Clicker™ Dispenser, The Ketac TM N100 light curing Nano Ionomer Restorative cement comes with a clicker dispenser containing two pastes and is designed to dispense equal volumes of each paste. The material was dispensed and mixed immediately prior to use to avoid water evaporation and drying out of the pastes. The exact steps to be followed are as listed, the cap removed from the Clicker dispenser by holding down the cap lever and sliding the cap off of the dispenser. Clicker lever fully depressed to dispense Ketac Nano restorative onto a glass slab. Paste allowed to fully extrude for 2-3 seconds and lever released. Dispensing process repeated for additional material. The paste was automatically dispensed in equal volumes. The actual weight ratio dispensed is (1.3/1.0). The dispenser tips were wiped clean with gauze to prevent cross contamination of the two pastes after the dispensing procedure was completed. The cap was replaced by sliding onto dispenser until securely latched and an audible click was heard. Mixing using a sterile agate spatula, the pastes were mixed together for 20 seconds until a uniform color was achieved. Avoiding the incorporation of air bubbles.

Materials were placed into preparation using conventional plastic (cement carrier) instruments. Placement of the dental instruments used for shaping and contouring were wetted with Ketac Nano Primer to prevent glass ionomer restorative from adhering to them. Working time was slightly lesser of about 2 minutes and 15 seconds due to the increased temperature. Later the Ketac Nano restorative was placed in the cavity and light cured to attain the final set of the material.

Restorative Technique

Bilateral class I cavities were prepared on mandibular second primary molars using a high speed Airotor with coolant. The cavity depth was standardized at 2mm by using a sterilized Periodontal Probe with William's markings then the isolation of the prepared tooth surfaces was achieved by placing cotton wool rolls and a high speed suction in place. The restorative material was then dispensed, mixed and carried to the tooth with a

conventional plastic filling instrument (cement carrier) and condensed into the cavity, excess was burnished against the cavity margins & care was taken to prevent heavy occlusal forces on the restorations. After the placement of the restorations, Radiovisiograph were taken bilaterally of both the lower 2 nd primary molars for baseline evaluation of the restorations.

Assessment of Restorations

Assessment of the restorations was done using a sterilized mouth mirror and dental probe/explorer and by taking IOPA’s of the teeth. For this modification of the United States public health criteria was used. The restorations were judged clinically and radio graphically by two different assessors for marginal adaptation & presence of secondary caries according to the following scale mentioned.

Clinical evaluation according to the marginal adaptation of the restorative material

Score 1:- Restoration adapts closely to the tooth along margins ,Score 2:- Clinically evident gap between restoration & cavity margins, Score 3:- Poor marginal adaption with obvious gap with or without caries, restoration needs replacement, Score 4:- Loss of restoration (complete failure of the treatment)

Radiographic evaluation according to presence or absence of secondary caries:

Score 1:- Not observed (successful) , Score 2:- Present radio graphically (not acceptable) [6].

RESULTS

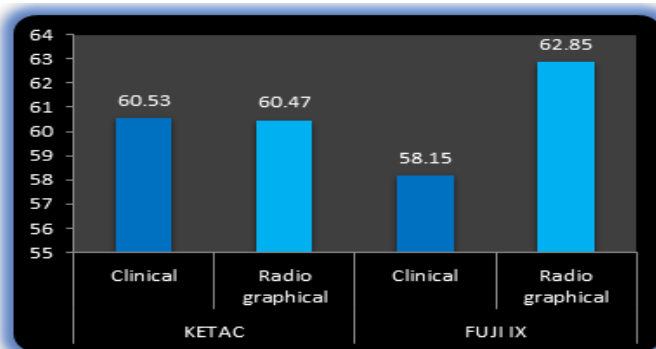
The study was designed and conducted in the Department of Pedodontics and Preventive Dentistry, Narayana Dental College and Hospital, Nellore, A.P. All 60 children completed the trail from base line evaluation over a period of six months. The data of the study are represented in the following tables and graphs.

Table 1: Comparison of conventional GIC (Fuji IX) and Light cured nano Ionomer (Ketac Nano) restorative materials after 6 months in all the 60 children w.r.t the 2 evaluation methods clinical and radiographical.

Evaluation Type	Methods	Mean Rank	Z – statistic	Mann – Whitney U statistic	p-value
Clinical	KETAC	59.13	0.806	1742.00	0.420 (NS)
	FUJI IX	61.47			
Radiographical	KETAC	57.00	2.205	1590.00	0.027 (S)
	FUJI IX	64.00			

S = Significant at 5 % level ;NS = Not Significant at 5 % level

FIGURE 1: Comparison of conventional GIC (Fuji IX) and Light cured nano Ionomer (Ketac Nano) restorative materials after 6 months in all the 60 children w.r.t the 2 evaluation methods clinical and radiographical.



The comparison of conventional GIC (Fuji IX™) and Light cured nano Ionomer (Ketac Nano™) restorative materials after 6 months in all the 60 children w.r.t the two evaluation methods, clinical and radiographical, was done and the results were not significant clinically ($p = 0.420$) and when compared radiographically for presence of secondary caries there were significant results and the ($p = 0.027$) as shown in table 1 and figure 1

Table 2: Comparison of the 2 methods Clinical and Radiographical w.r.t 2 materials conventional GIC (Fuji IX) and Light cured nano Ionomer (Ketac Nano) restorative materials after 6 months in all the 60 children.

Methods	Evaluation Type	Mean Rank	Z – statistic	Mann – Whitney U statistic	p-value
KETAC	Clinical	60.53	0.034	1798.00	0.973 (NS)
	Radiographical	60.47			
FUJI IX	Clinical	58.15	0.170	1659.00	1.374 (NS)
	Radiographical	62.85			

NS = Not Significant at 5 % level

When the comparison of the 2 methods, Clinical and Radiographical w.r.t two materials conventional GIC (Fuji IX) and Light cured nano Ionomer (Ketac Nano) restorative materials were made after 6 months in all the 60 children. The results for both Ketac Nano restorative material and conventional GIC (Fuji IX) were statistically not significant for Ketac ($p = 0.973$) and Fuji ($p = 1.374$) as shown in table 2 and figure 2.

FIGURE 2: Comparison of the 2 methods Clinical and Radiographical w.r.t 2 materials conventional GIC (Fuji IX) and Light cured nano Ionomer (Ketac Nano) restorative materials after 6 months in all the 60 children.

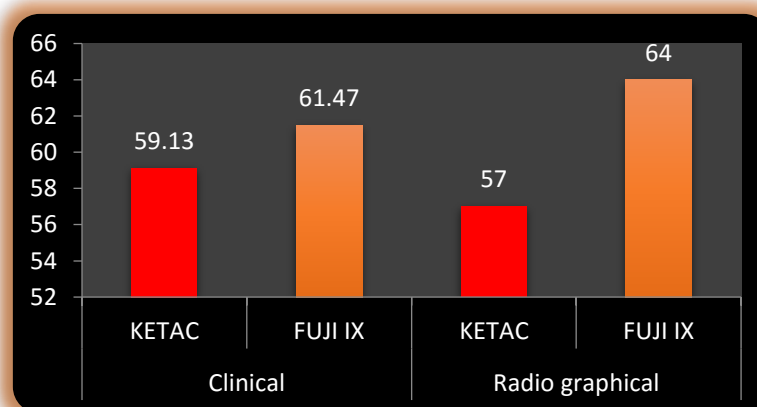


Table 3: Comparison of conventional GIC (Fuji IX) and Light cured RMGIC (Ketac Nano) restorative materials after 6 months in Boys.

Evaluation Type	Boys	Mean ± S.D	Z – statistic	p-value
Clinical (N =30)	KETAC	1.10 ± 0.548	2.000	0.046 (S)
	FUJI IX	1.17 ± 0.592		
Radiographical (N =30)	KETAC	1.03 ± 0.183	1.414	0.157 (NS)
	FUJI IX	1.17 ± 0.379		

S = Significant at 5 % level
NS = Not Significant at 5 % level

The conventional GIC (Fuji IX) and Light cured RMGIC (Ketac Nano) restorative materials were compared after 6 months clinically for marginal adaptation and radiographically for presence of secondary caries in boys. Clinically, the results for RMGIC (Ketac Nano) restorative material were statistically significant ($p = 0.046$) whereas, radiographically it was not significant as shown in table 3 and figure 3.

FIGURE 3: Comparison of conventional GIC (Fuji IX) and Light cured RMGIC (Ketac Nano) restorative materials after 6 months in Boys

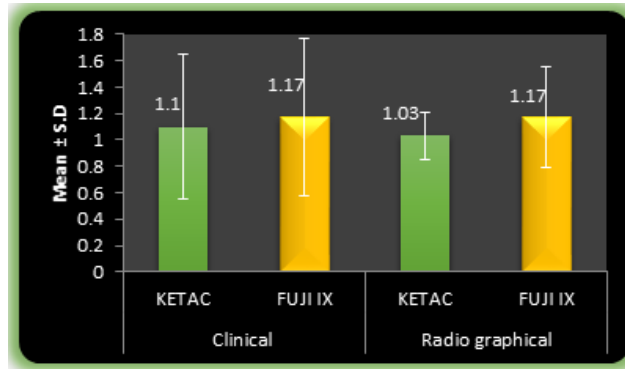


Table 4: Comparison of conventional GIC (Fuji IX) and Light cured RMGIC (Ketac Nano) restorative materials after 6 months in Girls.

Evaluation type	Girls	Mean ± S. D	Z – statistic	p-value
Clinical (N =30)	KETAC	1.10 ± 0.548	0.000	1.000 (NS)
	FUJI IX	1.10 ± 0.548		
Radiographical (N =30)	KETAC	1.03 ± 0.183	1.732	0.083 (NS)
	FUJI IX	1.13 ± 0.346		

NS = Not Significant at 5 % level

When the conventional GIC (Fuji IX) and Light cured RMGIC (Ketac Nano) restorative materials were compared after 6 months clinically for marginal adaptation and radiographically for presence of secondary caries in girls, there was no statistically significant difference between the two restorative materials as shown in table 4 and figure 4.

FIGURE 4 : Comparison of conventional GIC (Fuji IX) and Light cured RMGIC (Ketac Nano) restorative materials after 6 months in Girls

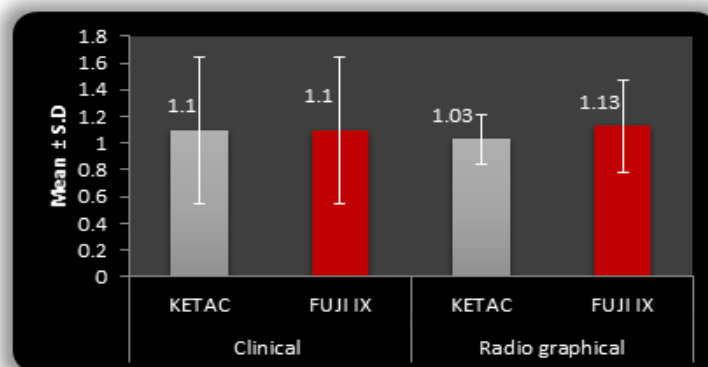


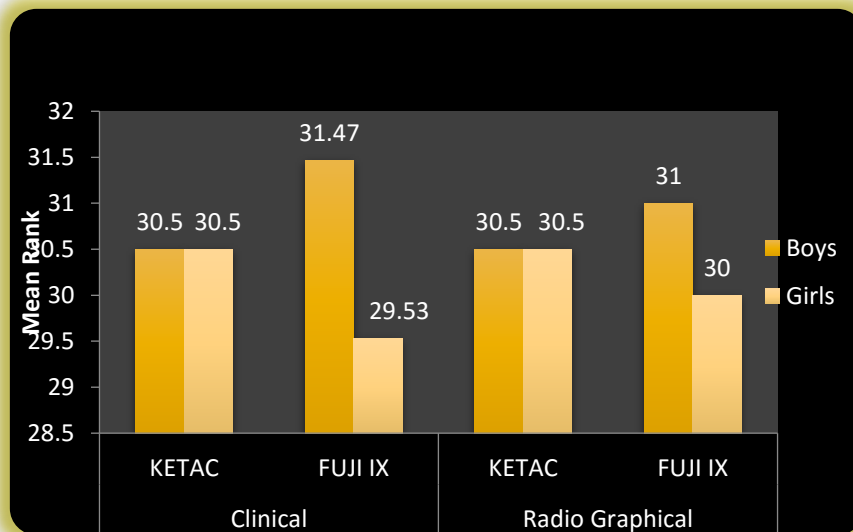
Table 5: Comparison of conventional GIC (Fuji IX) and Light cured RMGIC (Ketac Nano) restorative materials after 6 months between Boys and Girls.

Evaluation Type	Method	Gender	Mean Rank	Mann-Whitney U Statistic	Z	p-value
Clinical	KETAC	BOYS	30.50	450.000	0.000	1.000 (NS)
		GIRLS	30.50			
	FUJI IX	BOYS	31.47	421.000	0.992	0.321 (NS)
		GIRLS	29.53			
Radiographical	KETAC	BOYS	30.50	450.000	0.000	1.000 (NS)
		GIRLS	30.50			
	FUJI IX	BOYS	31.00	435.000	0.359	0.720 (NS)
		GIRLS	30.00			

NS = Not Significant at 5 % level

When the conventional GIC (Fuji IX) and Light cured RMGIC (Ketac Nano) restorative materials were compared after 6 months clinically for marginal adaptation and radiographically for presence of secondary caries between boys and girls there was no statistically significant difference between the two restorative materials as shown in table 5 and figure 5.

FIGURE 5: Comparison of conventional GIC (Fuji IX) and Light cured RMGIC (Ketac Nano) restorative materials after 6 months between Boys and Girls



DISCUSSION

Pediatric Restorative Dentistry plays a major role in the management of carious primary teeth. Pediatric Dentistry has come a long way, retrospectively different tooth colored restoratives were used to treat carious teeth and the first of them being the silicate cements till the emergence of GICs, the present era of Nano technology has given a new dimension to all aspects of dentistry including restorative dentistry, by incorporating nano sized filler particles in According to AAPD consensus in April 2002 and guidelines for Pediatric restorative dentistry, which were followed in the study.

- Restorative treatment should be based upon the results of an appropriate clinical examination and ideally be part of a comprehensive treatment plan. The treatment should take into consideration, the

- development status of the dentition, a caries risk assessment, the patient oral hygiene, anticipated parental compliance and likelihood of timely recall, the patient's ability to co-operate for the treatment.
- Restoration of primary teeth differs significantly from restoration of permanent teeth, due to the differences in tooth morphology, convergence towards the occlusal surface, thickness of the enamel, orientation of the enamel rods in the cervical region and also the pulp chambers of the primary dentition are proportionately larger and closer to the occlusal surface. Shorter clinical crown of primary teeth also affect the ability of these teeth to adequately support and retain intracoronal restorations.
 - Tooth preparation should include the removal of caries or improperly developed tooth structure to establish appropriate outline, resistance, retention and convenience form compatible with the restorative material to be utilized.
 - Glass ionomers have been used as restorative cements, cavity liner/base and luting cement. The initial glass ionomer materials were difficult to handle, exhibited poor wear resistance, and were brittle. Advancements in glass ionomer formulation led to better properties, including the formation of resin-modified glass ionomers. These products showed improvement in handling characteristics, decreased setting time, increased strength and improved wear resistance. Glass ionomers have several properties that make them favorable to use in children, Chemical bonding to both enamel and dentin, thermal expansion similar to that of tooth structure, Biocompatibility Uptake and release of fluoride Decreased moisture sensitivity when compared to resins
 - Fluoride is released from glass ionomer and taken up by the surrounding enamel and dentin, resulting in a tooth that is less susceptible to acidic challenge. Studies have shown that fluoride release can occur for at least 5 years. Glass ionomers can act as a reservoir of fluoride, as uptake can occur from dentifrices, mouth rinses and topical fluoride applications[7].

At the age of 4 to 7 years the mandibular second primary molars would have completely erupted in the oral cavity and are more susceptible to carious attack. The children in the present study were involved to evaluate the selective removal of carious dentin using rotary instruments and care was taken to radiographically examine and confirm pulpal involvement in the selected subjects. Even though it is impractical to expect standard oral conditions among the study population, patients were selected according to stringent criteria in order to achieve some de equivalence. There are different designs to select the affected teeth. The split-mouth design is one among these designs which was chosen, so that the two restorative materials would be exposed to a nearly identical oral environment. In most cases, the requirement for inclusion was the presence of at least two occlusal dentin lesions in need of restorative treatment present bilaterally in the mandibular second primary molars. The children included were falling into these mentioned criteria and were also relatively young at the time of restoration (4 to 7 years)[6].

The conventional glass ionomers are hydrophilic and tolerate a moist environment. Their ability to adhere, seal and protect the tooth structure makes them suitable to be used as dentin replacement materials, as their coefficient of thermal expansion is similar to dentin, as stated by Yilmaz et al. [8] The high-viscosity GICs used, in primary molars have a high powder liquid ratio and a higher compressive strength of about 182 MPa which attributes to their success rates in the primary dentition[8]

According to Alireza. M et al, incorporation of smaller size, apatite nanoparticles into powder of GIC, led to wider particle size distribution (the average particle size of glass-ionomer particles were around 10 to 20 μm) which resulted in higher mechanical values. Consequently, they can occupy the empty spaces between the glass-ionomer particles and act as a reinforcing material in the composition of the glass-ionomer cements. In addition, the presence of fluoride in the fluoride-substituted apatite has the potential to increase the amount of fluoride release from the set GICs[9].

The Resin-modified nano ionomers used in the present study have improved wear resistance compared to the conventional glass ionomers which may attribute to the fact that, it has increased density of the filler content and smaller filler particle size of about 20 nano meters, make them appropriate restorative materials for primary teeth. In permanent teeth, resin-based composites have been proved to provide better esthetics and wear resistance than glass ionomers. J. Rutar et al stated that a similar trend was apparent when comparing the high powder: liquid ratio material Ketac Molar to the conventional GIC. In comparison the Nano Ionomer has a nano structural morphology that is a hybrid of resin modified glass ionomer and nano filled dental composite. Both the acid reactive glass fillers and the methacrylate functional nano fillers of the nano ionomer

are smaller than those of the conventional resin modified glass ionomer. The Nano Ionomer have fluoride release capability of resin modified GIC and nano fillers that provide strength and esthetic quality of nano filled dental composites [10].

The potential of nanofillers in polymers, nano-particles in general and carbon nanotubes modify material properties of polymers. A necessity of a proper dispersion as well as a possibility of orientating the nano particles is shown, in order to attain the best possible properties. However, the huge potential of nano fillers for an improvement of the fracture mechanical performance of polymer based materials could be highlighted, at very low filler contents, as stated by Mathias P.M. et al. [11].

The special features of Nano Ionomer restorative are the unique two part paste technology combined with nano filler technology. As such GIC cements contain a powder and liquid which are needed to be mixed that initiates the acid-base setting reaction of the cement. Whereas Nano Ionomer restorative were developed as a two part paste to provide faster, easier, less messy and more reproducible dispensing and mixing compared to powder liquid systems. Nanotechnology was used in the development to provide some value added features not typically associated with glass ionomer restorative materials. Generally glass ionomer restoratives can contain a broad range of particle sizes. Filler particle size can influence strength, optical properties, and abrasion resistance. By using bonded nano fillers and nano cluster fillers, along with Fluoroaluminosilicate (FAS) glass Nano ionomer restorative has improved esthetics, yet still provides the benefits of glass ionomer chemistry, such as fluoride release[12].

Nano Ionomer restoratives has a higher compressive strength compared to most other glass ionomer restorative materials, tensile strength is greater than conventional glass ionomers and Ketac™ Nano ionomer exhibits a lower modulus of elasticity than the majority of both resin modified and conventional glass ionomers. It is more wear resistant than the leading resin modified glass ionomers. For better adhesion Ketac™ N100 Primer is required as a adjunct with the Ketac™ N100 Light-Curing Nano-Ionomer restorative cement[12].

For clinical evaluation of the two materials the results were not significant ($p = 0.420$) and for radiographical evaluation the results were significant ($p = 0.027$) the representation of values was made for comparison of conventional GIC and nano ionomer restoratives w.r.t the two evaluation methods clinical and radiographical. This proves the increased mechanical strengths of the Nano Ionomers as they have a higher compressive and tensile strength and also a lower modulus of elasticity for their better clinical performance.

The representation of values was made for comparison of the two methods Clinical and Radiographical w.r.t the two study materials conventional GIC and Nano Ionomers. The results were found not significant for both nano Ionomer restorative material ($p = 0.973$) and conventional GICs the ($p = 1.374$) proving the longer retention periods of Nano Ionomers.

When both the genders were taken into consideration boys ($n=30$) showed statistically significant results for clinical evaluation type ($p = 0.046$) and not significant for radiographical evaluation ($p = 0.157$). It proves that both methods maintain same stability after the treatment duration in the group of 30 boys, the representation of values was made for girls ($n=30$). And the results were found statistically not significant for both clinical ($p = 1.000$), as well as radiographical ($p = 0.083$) evaluation types, proving that neither the age nor the caries experience of the child at the time of restoration significantly influenced the success rates.

The evaluation of inter groups in genders for Nano Ionomers and conventional GICs with respect to the two methods showed insignificant results for both materials in clinical evaluation type and for the radiographical type which denotes that both genders maintain same stability of the restorative materials after the treatment over duration of 6 months. There was no much difference in the retention or longevity of the two materials owing to the fact that all the children had similar dietary patterns and dwelled in an urbanized locality. Studies conducted by Kevin. J et al, showed the same findings as in our study stating resin-modified glass nano ionomer cement restorations appear to have demonstrated a better success rate than that of the conventional glass ionomer cement restorations[13].

This could be due to a well-controlled standardized research method used for the clinical comparisons. The standard depth of the cavities of 2mm was maintained by measuring with a graduated William's periodontal probe as this depth is ideal for the placement of restorative materials shown by J.Rutar et al. [14].

The acceptance of teeth to be included in the study was well-defined for experimental purposes. In typical clinical practice, glass ionomer cements usually are used in areas in which isolation is not ideal and where placement might affect the success of another restorative material (that is, resin composite). Placement of a restoration in a non-ideal environment would have a detrimental effect on its long-term clinical success. Likewise, the resin-modified glass nano ionomer cement restorations in this study performed better clinically than did the conventional glass ionomer restorations. As conventional glass ionomer cements exhibit less moisture resistance than do resin-modified glass nano ionomer cements[13].

Qvist et al, in their study reported longer survival period for RMGIC materials with cavity conditioning than without. Another possible explanation for the increased success rates of the nano ionomers could therefore be the use of a primer with Ketac Nano Ionomer securing a better adaptation of the restorative material to the cavity walls than the adaptation achieved with Fuji IX.[15].

S. H. Y. Wei et al, have stated that continual high-frequency, low-concentration fluoride release has been recommended as a desirable treatment strategy to prevent tooth demineralization and enhance remineralization. Since fluoridated dentifrices and fluoride rinses have been shown to inhibit tooth demineralization effectively, one would expect that fluoride-releasing materials would provide a similar or superior benefit. Patient compliance is necessary to provide fluoride to the oral cavity by use of dentifrices and rinses. The fluoride associated with the restorative material will be present after restorative placement, although use of additional fluoride (in the form of dentifrice and rinses) and even antibacterial agents may be necessary, depending on the patient's caries risk or challenge and so they were instructed to continue their daily oral hygiene maintenance at home and the use of a fluoridated tooth pastes. A demonstration of proper brushing methods was also given to all the patients [16].

In the present study both the restorative materials performed well, showing negligible scores for failures. But in agreement with previous reports the main reasons for failure were loss of retention and secondary caries due to the reduced strengths of the conventional GICs when compared to the Nano Ionomers of the RMGIC group where the failure rates were negligible. All failures in conventional GIC group were due to secondary caries occurred with the Fuji IX restorations. Few failures were observed radiographically as radiolucencies under the restorations and some failed restoration showed caries along the cavity margins. Loss of retention was less common with nano ionomers than with Fuji IX. This might be explained by the dual setting mechanism of Ketac ensuring a more complete hardening of the material and higher fracture toughness compared with Fuji IX and also the use of Ketac Primer along with the Ketac Nano restorative[11].

In the present study the results portrayed that when both the conventional GICs and the resin modified Nano Ionomers were compared, the newer Nano Ionomers encompassing Nano technology used with proper restorative technique and manufacturer's instructions performed better clinically but no much difference was evident for both the materials radiographically. This might attribute to the fact that Ketac N100 TM Nano Ionomer has Nano fillers which gives better color stability, high compressive as well as tensile strength and a lower modulus of elasticity.

CONCLUSION

The results of the present study depict the fact that both materials performed clinically good for a period of 6 months the resin-modified Nano Ionomers showed lower rates of failure and offered advantages over the conventional GIC for restoring class I caries in primary molars. A comparison of genders was done for evaluating the retention of the cements separately in boys and girls. It was noticed that neither the age nor the caries experience of the child at the time of restoration significantly influenced the success rates. Due to exfoliation of the primary teeth, follow up times in clinical trials on the survival of restorations in primary molars are often short and include a number of censored teeth which was not true in our study and all the sixty patients were available for the clinical as well as radiographical evaluation after 6 months of follow up period. Resin-modified Nano ionomer restorative material functions well with enhanced longevity for Class I restorations in primary molars and exhibits less recurrent caries at restoration margins than conventional glass ionomers. The primer must be always used along with the light cured RMGICs, especially at dentin surfaces. Despite good potential of Ketac N100 TM Nano Ionomer restorative material, further clinical studies are necessary to confirm its bonding effectiveness as well as its better overall performance as a restorative material, particularly with regard to esthetics and wear degradation. The two paste approach and specific delivery device favors the ease

of use and may reduce the technique sensitivity. As a whole Keatc N100 light cured nano restorative incorporated with nano technology is an appropriate restorative material for Class I caries in the primary dentition.

REFERENCES

- [1] Theodore P. Croll, Yael bar Zion, Adriana Segura and Kevin J. Donly Clinical performance of resin-modified glass ionomer cement restorations in primary teeth. A retrospective evaluation JADA, Vol. 132, August 2001.
- [2] Diaz-Arnold AM, Holmes DC, Wistrom DW, Swift EJ. Short term fluoride release uptake of glass ionomer restoratives. Dent Mater 1995; 11:96-101.
- [3] Mitra SB. Adhesion of dentin and physical properties of a light cured glass ionomer liner or base. J Dent Res 1991; 70(1):72-4.
- [4] Hicks J, Flaitz CM, Silverstoen LM. Secondary caries formation in vitro around glass ionomer restorations. Quintessence Int 1986; 17(9):527-32.
- [5] A.R Prabhakar, O.S Raju, A.J Kurthkoti, V. Satish. Evaluation of the Clinical Behavior of Resin Modified Glass Ionomer Cement on Primary Molars: A Comparative One-year Study Journal of Contemporary Dental Practice, Volume 9, No. 2, February 1, 2008.
- [6] Guideline on Pediatric Restorative Dentistry, American Academy of Pediatric Dentistry, revised 1998, 2001 and 2004.
- [7] S. Hubel, I. Mejare. Conventional versus resin-modified glass-ionomer cement for Class II restorations in primary molars. A 3-year clinical study International Journal of Paediatric Dentistry Volume 13 Issue 1 Page 2-8, January 2003.
- [8] Yilmaz, Ozge. E, Nihal Belduz. A One-Year Clinical Evaluation of a High- Viscosity Glass Ionomer Cement in Primary Molars. The Journal of Contemporary Dental Practice, Volume 7, No. 1, February 15, 2006.
- [9] Alireza M, Sahar A, Maryam M, Nima R, J A. Darr and I Rehman, Effects of incorporation of hydroxyapatite and fluoroapatite nanobioceramics into conventional glass ionomer cements (GIC), Acta Biomaterialia 2008 (4) 432-440.
- [10] D. Versluis, R. DeLong, Characterization of Nano Ionomer Dental Material. NNIN University of Minnesota – 2007
- [11] Mathias C.M, B Fiedler, Florian H. Gojny, Malte H.G. Wichmann, Nolte, Karl Schulte Fundamental aspects of nano-reinforced composites. Composites Science and Technology 66 (2006) 3115-3125
- [12] Technical product profile Ketac N100 Light curing Nano Ionomer Restorative. 3M ESPE
- [13] Kevin J. D, A. Segura, Michael K, R.L. Erickson, Clinical performance and caries inhibition of resin-modified Glass Ionomer Cement and Amalgam restorations JADA, Vol. 130, October 1999 pg 1459 – 1466.
- [14] J. Rutar, L. McAllan and M. J. Tyas Three-year clinical performance of glass ionomer cement in primary molars International Journal of Paediatric Dentistry 2002; 12: 146-147.
- [15] V. Qvista, E. Manscherb, P.T. Teglers Resin-modified and conventional glass ionomer restorations in primary teeth: 8-year results Journal of Dentistry (2004) 32, 285-294.
- [16] K. M. Y. Hse, S. K. Leung, S. H. Y. Wei Resin-ionomer restorative materials for children: A review Australian Dental Journal 1999;44:(1):1-11